


# ITS.

Implants  
trauma



## SR

Sacral Rods



## Contents

### 1. Introduction

- P. 5 Preface
- P. 6 Properties
- P. 7 Indications & Contraindications

### 2. Surgical Technique

- P. 8 Ventral stabilization
- P. 8 Dorsal stabilization
- P. 9 Preparation
- P. 9 Reduction
- P. 9 Guiding instrument
- P. 10 Surgical Technique
- P. 11 Wedge shaped washers
- P. 12 Surgical Technique
- P. 12 Check
- P. 13 Postoperative treatment
- P. 13 Explantation

### 3. Information

- P. 15 Dotize®
- P. 16 Order list
- P. 18 Notes

# Introduction



## ◦ Preface

The operative management of pelvic ring disruptions has always represented a challenge to the treating surgeon. The sufficient stabilization of such an injury requires both a profound knowledge of the anatomy and biomechanics of the pelvis and an understanding of the mechanism of fracture.

The chosen technique of a posterior stabilization depends on the one hand on the kind of fracture, and on the other hand on the personal experience of the individual operator.

Threaded rods as fixators of posterior pelvic ring instability have been well known and well proven for a long time, especially for sacral fractures in all three zones and for detachments of the SI joint.

The stability of Sacral Rods has been proved in numerous studies, and in many investigations the rods have been used as a “gold standard” and reference value.

In the case of type C injuries, surgical intervention has first to be ventrally undertaken as a rule by means of plate osteosynthesis.

With the present technically perfected armamentarium, the technique has been standardized and considerably simplified.

The use of titanium plates imposes no restrictions on postoperative imaging diagnostics.



## ○ Properties

### Properties of the material:


- ♦ Material: TiAl6V4 ELI
- ♦ Easier removal of the implant after the fracture has healed
- ♦ Improved fatigue strength of the implant
- ♦ Reduced risk of inflammation and allergy

### Properties of the implant:

- ♦ Threaded rods with washers and locknuts for ilio-iliac compression osteosynthesis
- ♦ Simple and safe operative technique
- ♦ Low possibility of iatrogenic injury to neural structures
- ♦ Stepped thread to increase fatigue strength
- ♦ Socket spanner system with AO standard adapter for fast and simple fastening of nuts

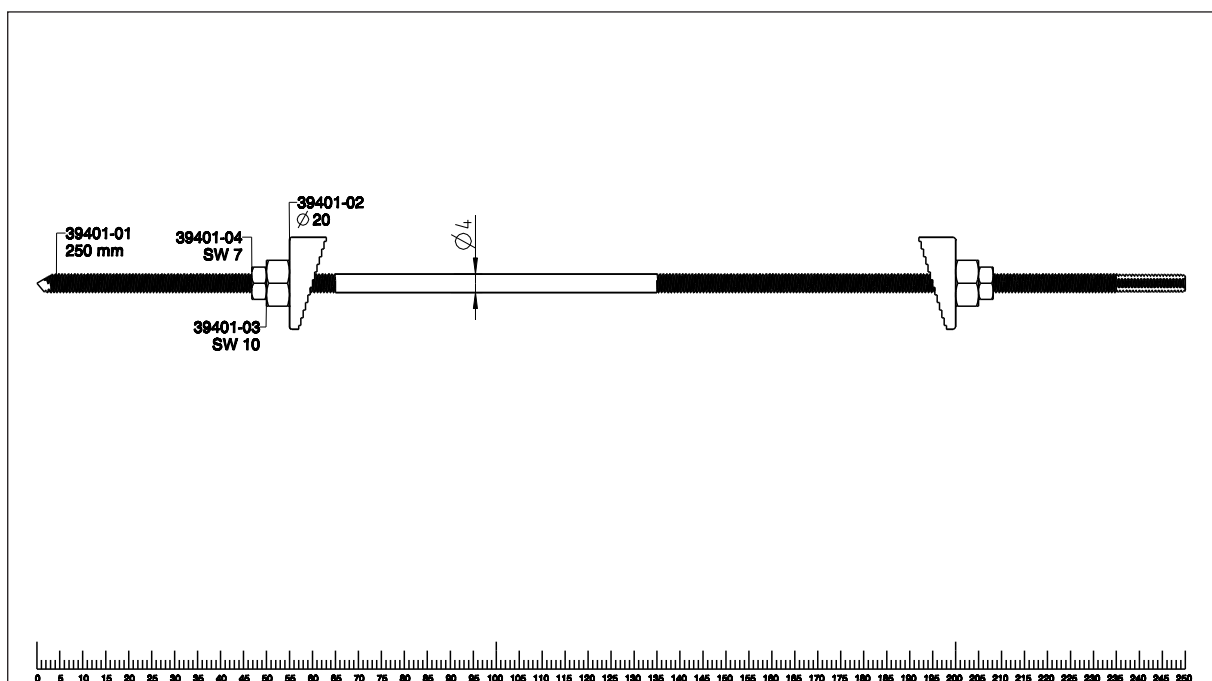
### Washer:

- ♦ Wedge-shaped
- ♦ Ribbed



### Guiding instrument:

- ♦ Stable guiding instrument for simple and safe positioning of threaded rods



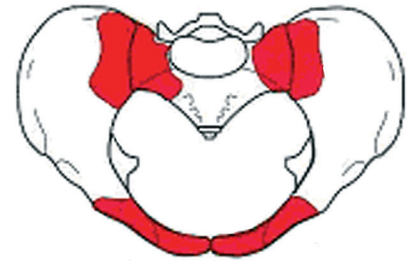
## ◦ Indications & Contraindications

### Indications:

- ♦ Dorsal stabilization on the posterior pelvic ring for unstable pelvic ring injuries type C/AO

### Especially in the case of:

- ♦ Unstable sacral fractures in all three zones
- ♦ Osteo-ligament instabilities of the sacro-iliac joint



### Contraindications:

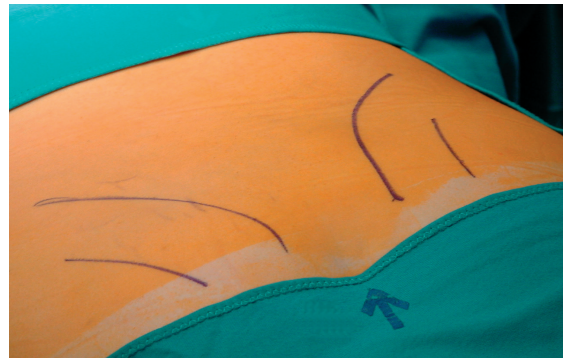
- ♦ Fractures of the ala of the ilium in the posterior area
- ♦ Fractures of the Os sacrum in the transforaminal area with CT-verified fractured parts and fragments requiring an open revision and decompression
- ♦ For the case that the relevant anatomy appears to preclude a safe positioning of the rods behind the sacral canal (rare)
- ♦ Existing infections in the fracture zone and operation area
- ♦ Common situations that do not allow osteosynthesis
- ♦ Obesity
- ♦ Lack of patient compliance

## Surgical Technique

# 2.

## ○ Ventral stabilization

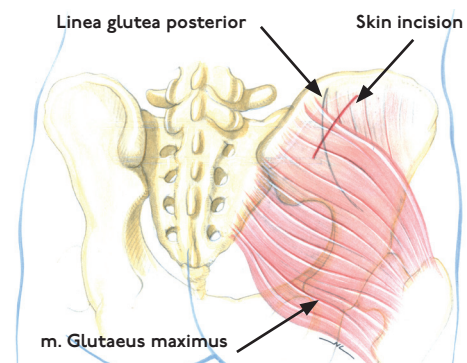
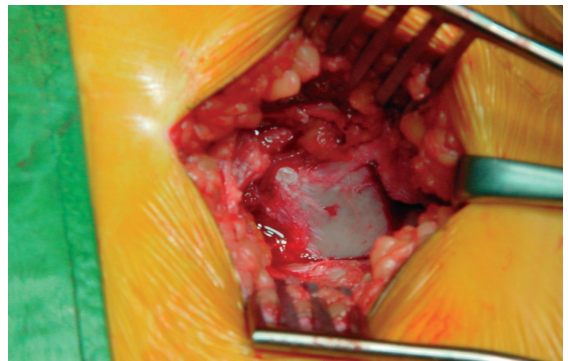
As a rule, a ventral stabilisation is carried out as the first intervention since a secondary reposition of the anterior pelvic ring in the case of an already reduced dorsal fracture could lead to an uncontrolled compression of the plexus sacralis.



## ○ Dorsal stabilization

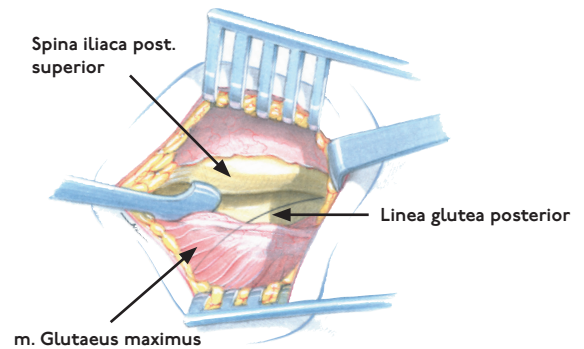
Dorsal stabilisation is carried out in the prone position of the patient, usually under full anaesthesia and in the same session.

A curved skin incision is made on both sides lateral to the sacro-iliac joint, from the spina iliaca posterior superior extending cranially with a length of about 5cm.



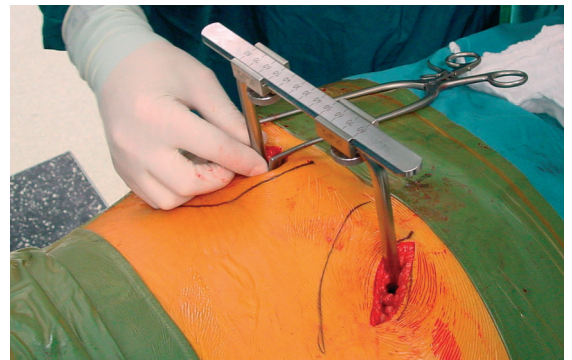
## ◦ Preparation

- Preparation of the subcutaneous fat tissue and carried down to the fascia of the gluteus maximus muscle.
- Loosen the musculature from the outer surface of the dorsal os ileum.



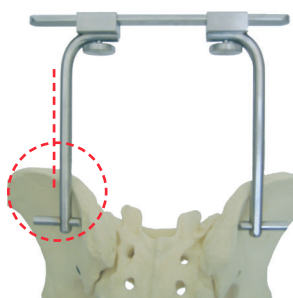
## ◦ Reduction

- A possibly necessary reposition of half of the pelvis is carried out by means of a Schanz screw attached to the crista iliaca.
- Deployment of the guiding instrument and checking by means of fluoroscopy.

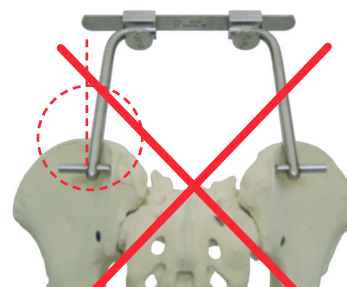

## ◦ Guiding instrument

It is strongly advised not to use the enclosed guiding device for reducing bone fragments since it could be damaged in this way and prevent a trouble-free attachment of the Sacral Rods.



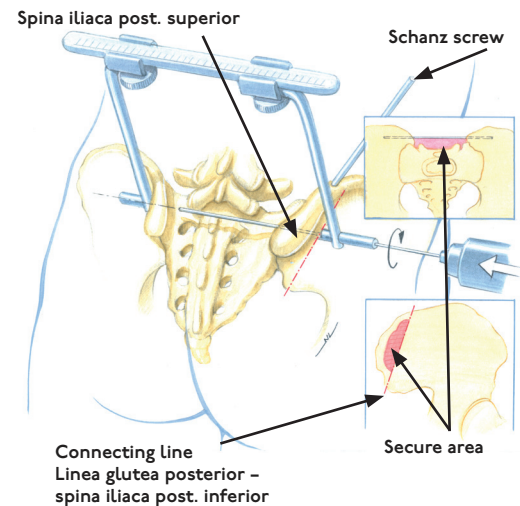
Right



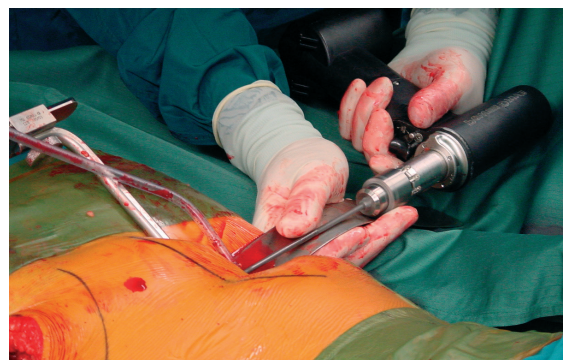
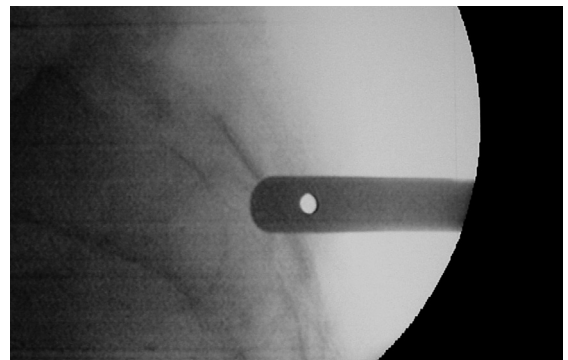
Wrong

## ◦ Surgical Technique

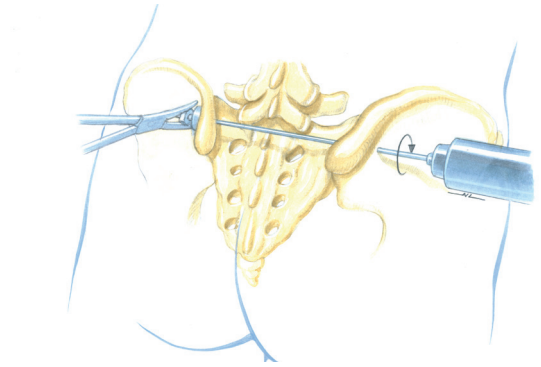
- The linea glutea posterior acts as the reference point.
- The guiding instrument is positioned on a considered line between the origin of the linea glutea posterior on the iliac crest and the spina iliaca inferior; the drill hole will then lie some 0.5cm higher.
- The caudal screw is attached first, and the point of entry is to be chosen such that the rod is at a tangent to the crista centralis of the os sacrum or even perforates it, but at least comes to rest behind the lamina dorsalis of the sacrum.



- The guiding instrument can be swivelled in the caudal direction during radioscopy (otherwise the guiding instrument can become loose due to divergence with the ala of the ileum).
- The threaded rod is equipped with a drill bit, and young bones should be predrilled. After that, the threaded rod is introduced over the guiding instrument.
- For predrilling we recommend the use of the enclosed drill to achieve a satisfying results.
- After the threaded rod has penetrated the second corticalis of the opposite os ileum, the guiding instrument is dismantled on this side.



- The asymmetric washer, nut and locknut are attached (this is done most simply by continuing to turn the rod with the drill).
- Both nuts must be definitively tightened.

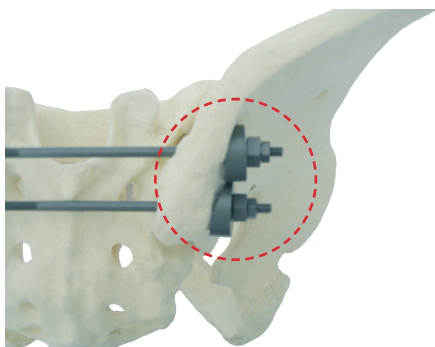


- The drill chuck is released, the guiding instrument removed, and the washer is attached as are, successively, both nuts on the second side using the special socket spanner and the soft-part protector.

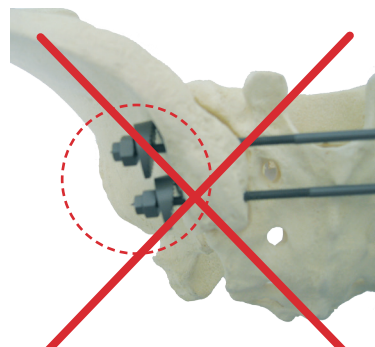


## ◦ Wedge shaped washers

Please note the exact anatomical position shown here to arrive at the best result.



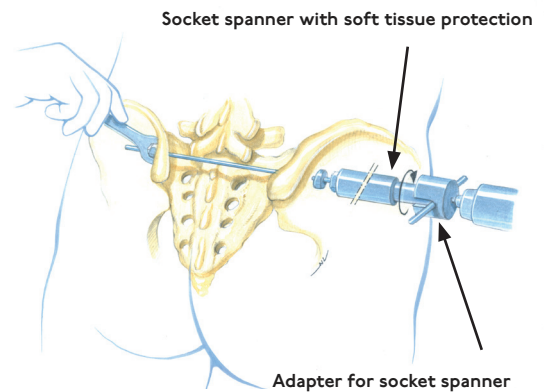
Right



Wrong

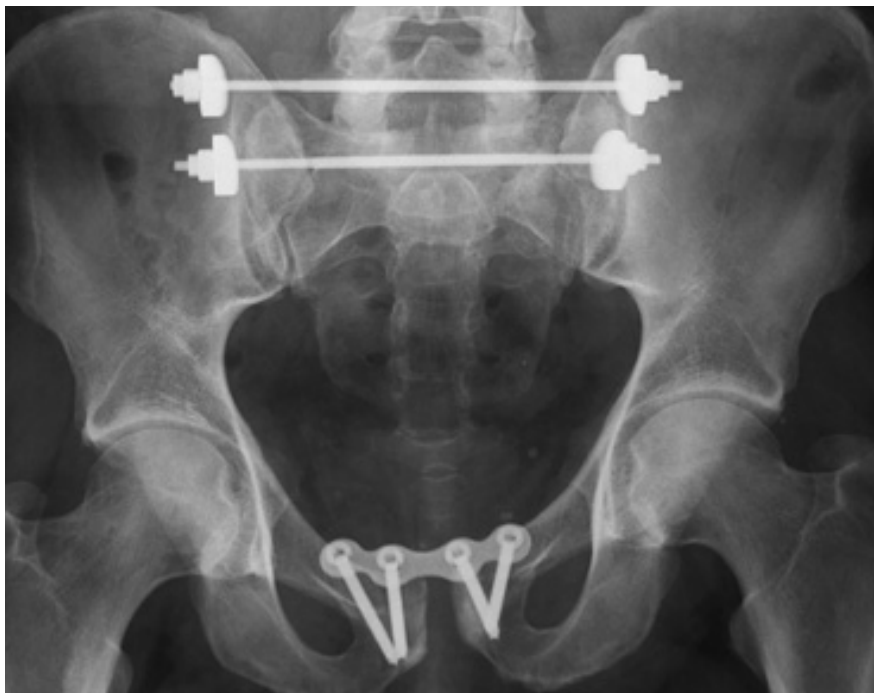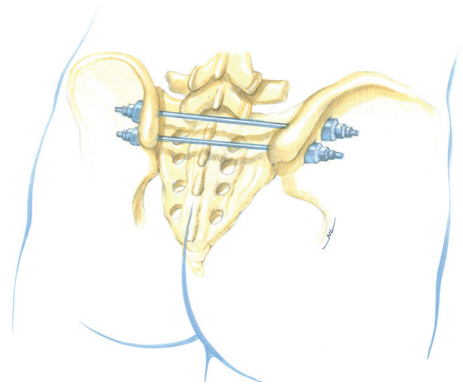
## ◦ Surgical Technique

The first nut is tightened until the desired compression of the fracture area is reached (care must be taken not to use excessive compression with transforaminal fractures of the sacrum.) Both nuts must be tightened. Remove the excess end using the bolt cutters. The same procedure is undertaken with the second screw, which is to be positioned some 2cm cranially to the first screw.



## ◦ Check

- ♦ Final check using fluoroscopy or X-ray
- ♦ Redon drainage
- ♦ Subsequent closure of the wound



## ◦ Postoperative treatment

Depending on type of fracture:

- In the case of instabilities of the SI joint and transalar fractures, we recommend partial stress of the injured side for six weeks, then moving on to full stress.
- In the case of transforaminal and central fractures, we recommend the injured side not be subject to stress for six weeks, then six weeks partial stress, moving on to full stress after CT check after the 12th week at the earliest.

## ◦ Explantation

The materials should be removed since two joints are bridged over.  
Removal of the implants is carried out as a rule after one year at the earliest.

Information

3.

## ○ Dotize®

### Chemical process - anodization in a strong alkaline solution\*

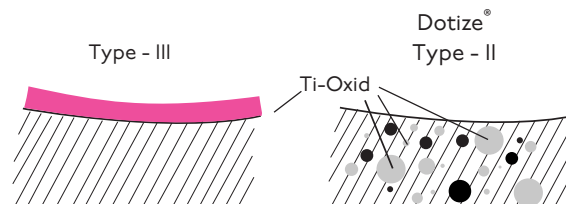
#### Type III anodization

- ♦ Layer thickness 60-200nm
- + Different colors
- Implant surface remains sensitive to:  
Chipping  
Peeling  
Discoloration

#### Dotize

#### Type II anodization

- ♦ Layer thickness 2000-10 000nm
- + Film becomes an interstitial part of the titanium
- No visible cosmetic effect



### Anodization Type II leads to following benefits\*

- ♦ Oxygen and silicon absorbing conversion layer
- ♦ Decrease in protein adsorption
- ♦ Closing of micro pores and micro cracks
- ♦ Reduced risk of inflammation and allergy
- ♦ Hardened titanium surface
- ♦ Reduced tendency of cold welding of titanium implants
- ♦ Increased fatigue resistance of implants
- ♦ Improved wear and friction characteristics

## ◦ Order list

Sacral Rod, Threaded	39401-01
----------------------	----------

Washer, Wedge-shaped, Ribbed	39401-02
------------------------------	----------

Nut, Gauge 10	39401-03
---------------	----------

Counternut, Gauge 7	39401-04
---------------------	----------

Guiding Instrument, 5 Parts, Sacral Rod	62403
---	-------

Socket Spanner, WS 7, L=240mm	56702-240
Socket Spanner, WS 10, L=200mm	561002-200

Tissue Protection Sleeve	62160-180
--------------------------	-----------

Spiral Drill, D=4.0mm, L=225mm	61403-225
--------------------------------	-----------


Flat Wrench, WS 7	70007
Flat Wrench, WS 10	70010

AO Screw Adaptor, Socket Wrench	53400
---------------------------------	-------

Bolt Cutter, Pelvis Screws, Sacral Rod	65394
--	-------

Sterilization Tray, Sacral Rods	50140
---------------------------------	-------

For detailed cleaning and sterilization instructions, please refer to package insert.



## Notes

This image shows a single sheet of white paper with horizontal blue ruling lines. The lines are evenly spaced and run across the width of the page. There are no margins, text, or other markings on the paper.





**ITS. GmbH**  
Autal 28, 8301 Lassnitzhöhe, Austria  
Tel.: +43 (0) 316 / 211 21 0  
Fax: +43 (0) 316 / 211 21 20  
office@its-implant.com  
www.its-implant.com



Order No. SR-OP-0218-E  
Edition: February/2018

© ITS. GmbH Graz/Austria 2018.  
Subject to technical alterations, errors and misprints excepted.